Scott Gorenstein, MD, FACEP
Clinical Director, Hyperbarid Medicine Program

Wound Healing Center and Hyperbaric Medicine
Winthrop-University Hospital
120 Mineola Blvd., Suite 360
Mineola, NY 11501.

PRELIMINARY EVALUATION ON THE APPLICATON OF A POWDER DRESSING IN THE FIXATION AND TREATMENT OF CHRONIC WOUNDS RESULTING FROM TRAUMA WITH EPIDERMAL SEPARATION

WINTHROP University Hospital
YOUR HEALTH MEANS EVERYTHING

Purpose

The purpose of this evaluation was to test a protocol in the management of chronic wounds resulting from trauma with epidermal separation combining a novel powder dressing for both fixation and moist wound healing.

Background

A common wound seen in wound care centers is a chronic wound resulting from trauma with epidermal skin separation. This primary acute wound is commonly called a skin tear and is typically found on elderly patients. This wound often becomes chronic if not treated properly. Skin tears have been identified as a common, acute injury sustained by the aged in extended care facilities [1-3] and changes to aging skin make this population more susceptible to skin tear injuries [1, 3-9]. A skin tear is defined as "A laceration of the epidermis, most often associated with minor trauma and involving a separation of the epidermis from the underlying connective tissue so that a flap of skin is created".

Methods:

Six patients were evaluated in a case series without controls. Patients ranged in age from 62 to 93 with a mean age of 76 years. For each patient, wounds were assessed and treatment history was documented. In all cases the trauma with epidermal separation occurred prior to referral to the wound center. The wounds were cleaned and the powder wound dressing was applied. The intact dressing was covered with a contact layer followed by a rolled gauze dressing and/or ace wraps for compression if indicated.. Patients were assessed at approximately 7 day intervals at which time the dressings were changed and the wound size and appearance were evaluated.

92 year old female with chronic wound resulting from skin tear on anterior tibial surface

Application of powder dressing after assessment and debridement

Day 28 after weekly evaluation and dressing changes

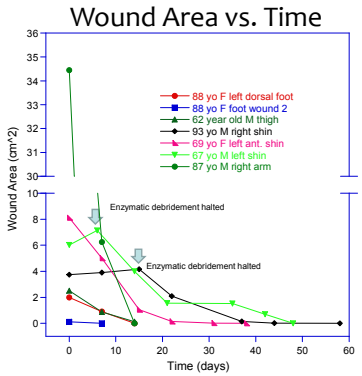

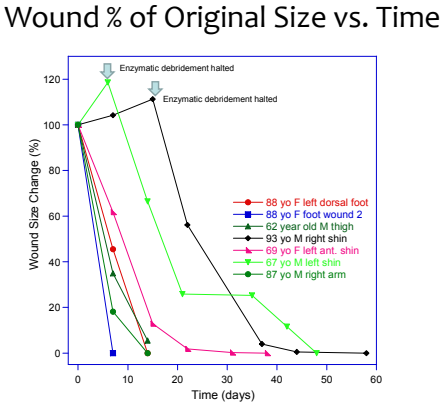

Results

For the patients evaluated, six (6) patients had a total of seven (7) wounds that healed using the powder dressing. No wounds failed to heal,. The data was not generated as a prospective clinical study with inclusion criteria. Data are shown below for wound healing with and without preriods of enzymatic debridement:

Parameter	Post Enzymatic Debridement	Debridement Included
Minimum Healing Time	7 days	7 days
Maximum Healing Time	36 days	48 days
Mean	19.8 days	24.6 days
Median	14 days	14 days
Std Deviation	10.5	16.4

Two patients showed an initial increase in wound area. These increases occurred with the application of an enzymatic debriding agent in conjunction with the powder wound dressing.

Of the six patients, only two reported pre-treatment pain. Both reported a decrease in pain after the application of the powder wound dressing. One reported a change from 8 to 1 with the application of the dressing on a pain scale of 1-10 (10 being the worst) and the other 5 to 0.

In all cases the dressing was applied without adhesive fixation and wrapped loosely in cotton gauze. The dressings were changed on a weekly schedule with the exception of two 14 day intervals when patients were not present for weekly dressing changes..

The dressing remained in place for all patients during the evaluation period.

Conclusions

The data shows that the powder dressing can be safely applied to a skin tear and used to anchor that tear during a treatment protocol with a 7 day interval between evaluations. A clinical study has been implemented using randomization and controls for the treatment of skin tears using this treatment protocol.

References

1. Malone M, Rozario N, Gavinski M & Goodwin J. The epidemiology of skin tears in the institutionalised elderly. Journal of American Geriatric Society 1991; **39 (6)**:591-595.
2. Everett S & Powell T. Skin tears – the underestimated wounds. Primary Intention 1994; **February**.
3. McGough J & Kopac C. Skin tears in the institutionalised elderly: an epidemiological study. Ostomy/Wound Management 1998; **44(3A) (Suppl) March**:14S-24S.
4. Thomas R, Goode P, LaMaster K, Tennyson T & Purnell LA. Comparison of an opaque foam dressing versus a transparent film dressing in the management of skin tears in institutionalised subjects. Ostomy/Wound Management 1999; **45(6)**:22-28.
5. Payne R & Martin M. The epidemiology and management of skin tears in the older adult. Ostomy/Wound Management 1990; **26(Jan/Feb)**:26-37.
6. Payne R & Martin M. Defining and classifying skin tears: need for a common language. Ostomy/Wound Management 1993; 39(5) June:16-25.
7. Mason S. Type of soap and the incidence of skin tears among residents of a long-term care facility. Ostomy/Wound Management 1997; 43(8) Sept:26-30.
8. Edwards H, Gaskill D & Nash R. Treating skin tears in nursing home residents: a pilot study comparing four types of dressings. International Journal of Nursing Practice 1998; 4:25-32.
9. Baranoski S. Skin tears: the enemy of frail skin. Advances in Skin and Wound Care 2000; May/June:123-126. ...

Comparison in Management of Large, Open Combat Wounds in Service Personnel Using Negative Pressure Wound Therapy as Standard of Care and a Novel Powder Dressing

Barry D. Martin, MD, FACS, LTC(P), Medical Corps, USA
Chief, Integrated Plastic Surgery Service, Consultant to The Surgeon General in Plastic Surgery
Walter Reed Army Medical Center/ National Naval Medical Center Washington, DC/ Bethesda, MD

2009 SAWC Meeting
Grapevine, Texas

Home of Warrior Care
WALTER REED
ARMY MEDICAL CENTER

Introduction

Combat trauma produces wound patterns that are seldom observed in civilian hospitals and require complicated surgery and post-operative care. The damage created by explosive devices depends on a number of factors, including the type of explosive, and the environment within which the detonation takes place. Injuries are dependent on the power of the explosion, the proximity of the casualty to the explosion and the environment (open or confined). When the energy of an explosion is directed towards tissue it creates a wound that is catastrophic to deep tissue and that will require surgical reconstruction until fully healed. In addition, this type of wound is universally accompanied by penetrating shrapnel which carries bacteria deep into the wound. Currently blast wounds in Uniformed Services Hospitals are managed uniformly with negative pressure wound therapy (NPWT), which is used to stabilize the wound, remove bacteria from tissue, and ultimately provide a well-vascularized granulation bed suitable for subsequent grafting.

This set of cases details the post-operative management of three combat trauma wounds where a combination of NPWT and a novel powder dressing are used to achieve closure.

Saphenous artery fasciocutaneous flap coverage of a posterior popliteal wound with exposed nerve from a rocket-propelled grenade attack in Iraq.
Patient is a healthy 38 year old male with a concominant closed head injury.
Initial treatment was serial debridements with VAC coverage for ten days. The procedure was complicated by superficial skin necrosis which was managed by debridement and NPWT (4 days) followed by skin grafting covered with the powder dressing for 10 days.

Patient is now five months post-injury with a healed wound pending secondary nerve grafting.

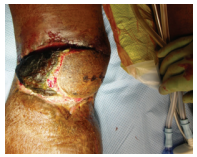

Partial Flap loss
Pre-debridement

Post-debridement

2 weeks post grafting

Latissimus dorsi myocutaneous free-tissue transfer with large skin grafts to the wound 2 weeks following injury.
Patient is a 26 year old male healthy medic who suffered an open fracture of his anterior knee/thigh with large soft tissue loss.
Initial pre-flap management was serial debridement and VAC dressings. Post-flap dressings were NPWT as a bolster over the recipient graft sites and the powder dressing to his skin-graft donor sites and the recipient site following removal of NPWT. The graft sites required two additional applications of the powder dressing until complete re-epithelialization occurred at 3 weeks following flap procedure.

Patient is now 3 months post-op with a healed wound and ambulatory. He is also currently being treated by osseous distraction/lengthening of his femur fracture. Patient will require subsequent tendon grafting to improve knee extension power.

Initial Wound following debridement
NPWT, and external distractor

Flap inset with
Surrounding Skin Grafts

Three weeks post-op

Anterolateral thigh free-tissue transfer and large skin grafting five months ago.
Patient is a 22 year old male healthy infantry soldier who suffered an IED blast injury to his lower leg and ankle with an open ankle fracture, exposed tendons and a segmental nerve deficit. The other injury was a traumatic below-knee amputation of the opposite leg.
Initial management was serial debridement, NPWTfor 10 days prior to free flap.
Post-op management was NPWT bolster over skin grafted areas with transition to powder dressing for two weeks (three applications required).

Patient is completely healed, ambulatory and awaiting nerve grafting

Initial wound following
debridement, and NPWT,

One week post free flap, powder
wound dressing in place

Three Weeks
Post Grafting

Discussion

Complicated trauma cases involve detailed assessment and planning prior to reconstructive surgery. The choice of techniques for post-operative management is critical and can often be overlooked after the surgical procedure is completed. For trauma cases involving reconstructive surgery with flaps or skin grafts, the conventional choice is NPWT or bolster dressing(s). These techniques are viable and functional options. A novel powder dressing was evaluated as a choice for covering and protecting a flap or mesh STSG after the application of NPWT. This technique was evaluated to determine if it was possible to transition from NPWT to the use of a unique powder dressing for closure. The data set is limited, however, the powder dressing does appear to cover and protect a wound during closure with dressing changes at intervals between 3 and 7 days.

Conclusions

It is possible to transition from NPWT to the use of a novel powder dressing in post operative care of combat trauma cases involving reconstructive surgery. Further studies as to the timing of the transition would benefit the development of best clinical practice for the use of this novel dressing.

Gregory A. Bohn, MD, FACS, Medical Director
Trinity Wound Care and Hyperbaric Medicine
Bettendorf, Iowa

Powder Dressing with high Moisture Vapor Transpiration Rate may have physical influence on wound healing

Background:
Hydrogels and hydrocolloid dressings have many favorable properties and improve wound healing while maintaining a moist wound environment (4). A new powder dressing conforms to the wound surface and has a high Moisture Vapor Transpiration Rate (1). Although the precise mechanism of action has not been determined, it is believed that this close contact and high moisture vapor transpiration rate (MVTR) creates a low pressure at the interface between the dressing and wound bed that stimulates the formation of healthy granulation tissue (2). This novel new dressing was placed on a post surgical foot wound that had not shown improvement with standard wound care.

Methods:
Standard wound measurements are recorded weekly as part of the patient's wound documentation. The timing of application of powder dressing technology to the wound was evaluated by observed change in wound volume over time. Wound volume was calculated using the formula: Wound Volume = Length x Width x Depth x .8. This data was then displayed in graph form (Figure 1) to observe the change with the application of this new dressing product.

Results:
The patient's wound did not demonstrate healing as measured by wound volume calculations in the first 4 weeks of wound care. The wound volume decreased precipitously after application of this powder dressing. The wound showed a decrease in volume measurement by 52.6% in the first week of dressing therapy. Volume reduction continued in the second week of therapy with the wound volume recorded measuring a 95.3% reduction in wound volume compared to the patients initial visit measurements. If the dressing creates a low pressure at the dressing - wound interface by way of the high Moisture Vapor Transpiration Rate promoting healthy granulation tissue formation, this dressing may stimulate healing by influencing physical characteristics of cells.

Case Study:
39 yo white male had suffered crush injury to the dorsum of his left foot. A split thickness skin graft was applied to cover the acute crush injury. Recent orthopedic corrective surgery was performed and resulted in a new skin and tissue deficit on the dorsum of his foot. He was referred to wound care to "clean up the wound in preparation for a skin graft". After 4 weeks of standard wound care, the wound had stagnated as tracked using standard wound volume measurement calculations. Powder dressing became available in our clinic and was applied to the wound. The dressing remained in place and was changed weekly at his clinic visit. Debridement was performed at each clinic visit. This patient experienced a rapid healing trajectory as demonstrated in Figure 1. His wound went on to heal without requiring an additional skin grafting procedure.

Initial Wound

Week 5 Post-debridement

Week 5 Altrazeal

Week 7

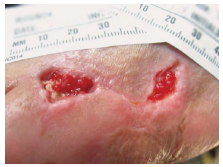

Week 7

Week 8

Week 8

Week 8

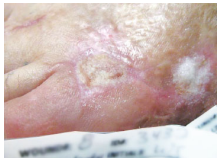

Healed

Powder Impact on Healing

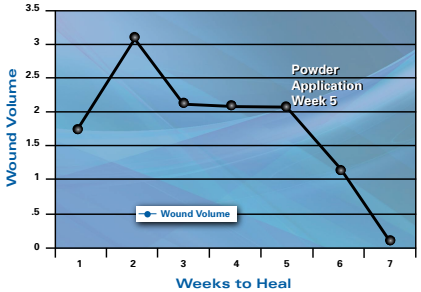

Figure 1

Mechanism of Action – Exudate Management



Powder Dressing
12,000g/m²/24 hours

Hydrocolloid
1100 g/m²/24 hours

Mechanism of Action – Physical Properties

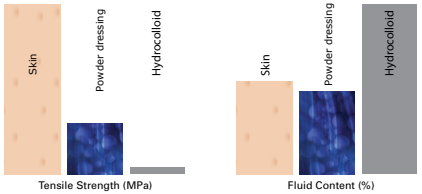

Conclusions:
Powder dressing applied to this wound promoted a vigorous granulation response and healed a wound expected to require a skin graft. The wound had not demonstrated significant progress in 4 weeks sufficient to predict healing based on well accepted parameters (7). After application of powder dressing, the wound started on a steep healing trajectory (fig. 1). This wound progressed and closed without requiring an additional operative procedure to skin graft.

Micro-stress on cell walls can cause cellular proliferation and favorably impact on wound healing (3). Given the high moisture vapor transpiration rate of this material compared to other dressings; 12,000g/m²/24hrs vs 1100 g/m²/24hrs (2), the dressing may have a physical affect on the proliferating cells, wound fibroblasts in the wound bed and the wound margin to promote granulation formation and healing. Once the dressing is formed, the particles create capillary forces that pull moisture into the dressing and it evaporates at the dressing air interface. This transpiration of moisture vapor pulls with a significant force and creates a pressure differential of 200-300 millitorr at the wound dressing surface (2). Negative pressure of as little as 100 millitorr produces stress on cells and brings about conversion into rapidly metabolizing fibroblasts (wound fibroblasts). Further work to better correlate this low negative pressure and its affect on wound fibroblasts and granulation tissue formation with subsequent wound healing would help in understanding the affects brought about with this dressing material.

References:
1.) St. John J V, Brown S A, Hatef DA, Unzeitig A W, Noble D, Waller L K, and Ponder B C. Formulation development and in vivo testing of a novel powder wound dressing. The University of Texas Southwestern Medical Center at Dallas, Department of Plastic Surgery, 1801 Inwood Rd., Dallas, TX 75390
2.) St John J V, Altrazeal TM : Transforming Clinical Wound Management: From Science to Outcomes with an Innovative Powder Dressing. Clinical Symposium on Advances in Skin & Wound Care. Oct 29, 2008 Las Vegas Nevada.
3.) Saxena V, Hwang C-W, Huang S, Eichbaum Q, Ingber D, Orgill DP. Vacuum-assisted closure: microdeformations of wounds and cell proliferation. Plastic and Reconstructive Surgery. 2004 Oct;114(5):1086-1096; discussion 1097-8
4.) Turner TD. Products and their development in wound management. Plast Surg Dermatol Aspects. 1979; 75-84
5.) Thomas S, Loveless P. A comparative study of the properties of six hydrocolloid dressings. Pharm J 1991; 247:672-675.
6.) Sharman D, Moist wound healing: a review of evidence, application and outcome – Review. Diabetic Foot, The Autumn 2003. 7.) Kantor J, Margolis DJ. Efficacy and Prognostic Value of Simple wound Measurements. Arch Dermatology. 1998; 134: 1571-1574.

TRINITY IOWA HEALTH SYSTEM
A better experience.

Diversified Clinical Services
Healing Wounds. Changing Lives.
ULURU, Inc.